

Therapeutic effect of MSB0052 on recurred lymphoplasmacytic lymphoma and malignant melanoma Case Reports

TAE YOUNG HAN. OMD

³Banronginsu Herb Clinic, Nonhyun-dong, Kangnam-gu, Seoul 111-24, Korea.

Introduction

MSB0052 is a herbal combination designed for cancer patients with Shao Yin (lesser Yin) constitution and has shown therapeutic effects previously in patients with different types of cancer. Here, I present a case with lymphoplasmacytic lymphoma and a case with locally recurred melanoma. Both received various regimen including MSB0052 with either single chemotherapy agent or with acupuncture and showed good response locally.

In my practice, I made herbal combination for each constitution and classified western medications into 4 groups (Taiyang, Shao Yang, Tai Yin, Shao Yin). According to my classification, oral 5 FU is classified as chemotherapy for Shao Yin type patients.

Case 1. Lymphoplasmacytic lymphoma

The patient is a 38 years old female who was diagnosed with lymphoma with palpable masses on neck ten years ago. And did not received any treatment without progression. Due to recent growth of neck mass, a biopsy was performed at University Hospital in June, 2009. Pathologic report revealed lymphoplasmacytic lymphoma.

Subsequently, an oncologist tried CHOP chemotherapy (cyclophosphamide, Adriamycin, vincristin, prednisolone) three cycles. After second CHOP therapy, CT scan (2009.7.22) showed size reduction in cervical lymph nodes. But soon after further CHOP therapy, CT and PET scans were done on Aug 2009 which showed apparent increase in nodal size at left level III-V. The patient did not receive any cancer treatment until another F/U CT scan on 2010.1.22 which showed more growth of cervical lymph nodes and new nodal mass at anterior mediastinum.

She visited our clinic afterward (2010.2.1) and started herbal therapy (MSB0052) and erythromycin, dexamethasone, and UFT on Feb. 2010 based on her constitution of Shao-Yin. The masses on the neck showed marked improvement after 1 month treatment. The CT scan (2010.3.17) showed notable disappearance of soft tissue lesion in the anterior mediastinum and of mass along posterolateral neck. And remained as near complete regression of anterior mediastinal mass and left neck mass on CT scan done in May 2010. Most recent clinical check-ups, she is in stable condition without any side effects.

Summary:

In a patient with recurred lymphoplasmacytic lymphoma after failure with CHOP chemotherapy, herbal combination (MSB0052) with single chemo agent of UFT based on her constitution was prescribed with good response of tumor within a month.

38세의 여환은 10년전에 목에 mass 가 축적되어서 림프종으로 진단받았지만 특별히 자라나지 않고 있다가 최근에 목에 mass 가 자라나 삼성의료원에서 2009년 5월 조직검사를 시행하고 Lymphoplasmacytic lymphoma 라는 드문 림프종으로 진단받았다. 이 림프종은 아직 특별한 치료법이 없어서 임상적으로 CHOP 이라는 항암제의 배합이 시도되고 있다. 이 환자는 CHOP (사이탁산, 아드리아마이신, 빈크리스틴, PD) 등의 약물로 3차례 항암치료를 받았는데 초기에는 약간 감소되다가 종양이 다시 악화되어서 병원에서 항암을 중지하고 관찰하였다. 2010.1.22 일 시행한 neck CT 상 경부의 외측을 따라 림프절들이 자라나고 종격 등의 앞쪽으로 새로운 림프절이 관찰되었다. 이후 환자는 본원에 2010.2.1 일 내진하여 본원의 항암약물인 MSB0052 를 시행받고 더불어서 EM, Dexa, UFT 등 본원에서 소용인 약물로 분류되고 있는 약물을 같이 처방받았다. 한달후인 2010년 3월 종양은 현저히 감소되어서 종격동에 보이던 종양은 거의 소실되었고 목의 바깥면을 따른 종양도 확연히 줄어들었다. 이후 2010년 9월 현재까지 종양의 특별한 재발이 없이 UFT 와 MSB0052 약물에 의존하여 어떤 부작용도 없이 stable 한 상태를 유지하고 있다.

Summary :

재발된 lymphoplasmacytic lymphoma 환자에게서 CHOP chemotherapy 의 실패이후에, 한약제인 MSB0052 와 복용하는 항암약물인 UFT 를 동시에 사용하여서 종양의 억제에 좋은 효과를 보인 예이다.

Pathology

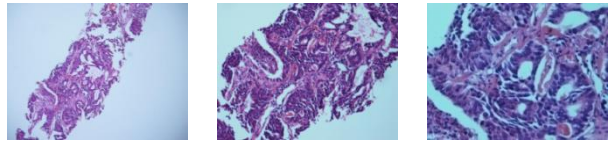


Figure 1. 10x

Figure 2. 20x

Figure 3. 50x

CT comparison 2010.1.22 with 2010.5.19.

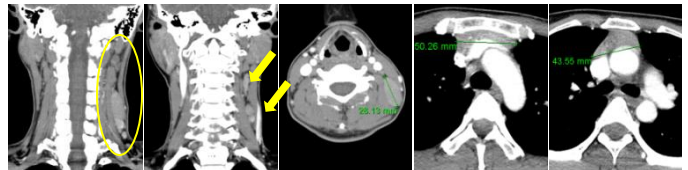


Figure 4. 2010.1.22

Figure 5. 2010.1.22

Figure 6. 2010.1.22

Figure 7. 2010.1.14

Figure 8. 2010.1.14

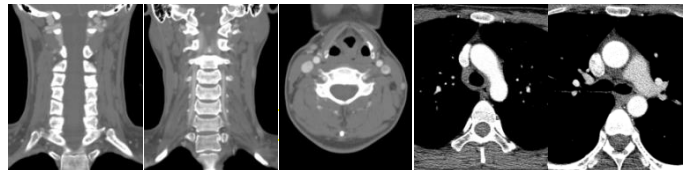


Figure 9. 2010.5.19

Figure 10. 2010.5.19

Figure 11. 2010.5.19

Figure 12. 2010.3.17

Figure 12. 2010.3.17

Case 2 . melanoma recurred after parotidectomy

A 73 years old female who was diagnosed with malignant melanoma (stage IV) had recurrences eight times at right face.

First surgical removal was in August 2008 and last operation was in March 2009.

After each dissection, her local tumor grew very rapidly and she was referred to our clinic in May 2009.

At first, she complained very severe pain around mass near right ear. She was treated with MSB0052 and acupuncture .

Soon after MSB0052 therapy, pain was subsided and rapidly growing nodules were slowly regressed as shown in figures.

After 3 months of therapy, her masses shrunk much more.

73세의 여환은 악성흑색종으로 삼성의료원 진단후 수술을 시행하였고, 계속 재발하여서 2009년 5월 본원에 내진전까지 모두 8차 이상의 흑색종 제거술을 시행받았다. 이후 또 급격히 자라나서 병원에서 치료를 포기하고 매우 심한 통증과 왼쪽귀 바깥으로 종양이 자라나서 본원에 내원하였다. 내원후 환자는 본원 약물인 MSB0052 를 시행받고 종양이 두달사이에 맑은 감소를 보였다.

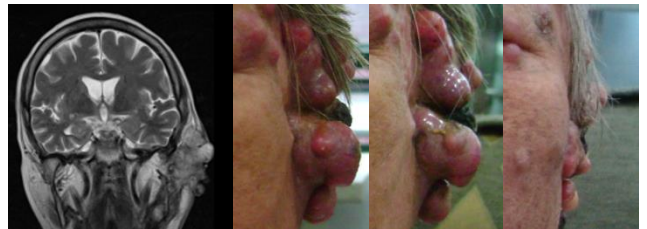


Figure1 MRI 2009.7.6

Figure 2 2009.6.9

Figure 3 2009.6.22

Figure-4 2009.8.18